

'Sperm Accumulation' in a Stallion

Patrick M. McCue, DVM, PhD,
Diplomate American College of Theriogenologists

History

A 15 year old American Quarter Horse stallion presented to the clinic for a breeding soundness evaluation (BSE) at the beginning of the breeding season. The referring veterinarian had collected semen the previous week and reported a high concentration of spermatozoa and all were dead. The stallion had been used for pasture breeding the previous year. The owner indicated that the seasonal pregnancy rate last year was good. However, he had observed that mares bred early in the season did not become pregnant; they did become pregnant on later cycles.

Physical Examination

The stallion was noted to be in good body condition and had an excellent disposition. Examination of his external genitalia revealed no significant abnormalities of his epididymides, spermatic cords, prepuce or penis. Both testes were fully descended into the scrotum and approximately equal in size and consistency.

Initial Semen Collection and Analysis

The stallion exhibited normal breeding behavior at the time of semen collection. His libido was excellent and he mounted the breeding phantom uneventfully. The stallion was collected twice, one hour apart. Semen analysis consisted of measurements of semen volume, sperm concentration, sperm motility, and sperm morphology. Volume was measured in a graduated cylinder; concentration of spermatozoa was determined using a calibrated spectrophotometer (ARS Densimeter); total and progressive sperm motility was evaluated by a computer assisted semen analysis (CASA) system; and sperm morphology was determined under a microscope after eosin-nigrosin staining.

Results of the two semen collections are presented in Table 1. The sperm concentration was greater than 400 million sperm per ml and the total number of sperm was over 30 billion in each of the two ejaculates. However, there were no live spermatozoa noted in either ejaculate. Less than 30 % of sperm were morphologically normal, with the most common abnormality being detached heads (approximately 40 %) (Fig. 1).

Table 1. Semen parameters for two ejaculates collected one hour apart.

Parameter	Collection # 1	Collection # 2
Gel-free Volume (mls)	64	80
Sperm Concentration (million/ml)	482	414
Total and Progressive Motility (%)	0/0 %	0/0 %
Morphology (% normal sperm)	20.5 %	28 %
Total # sperm in ejaculate (billions)	30.85	33.12

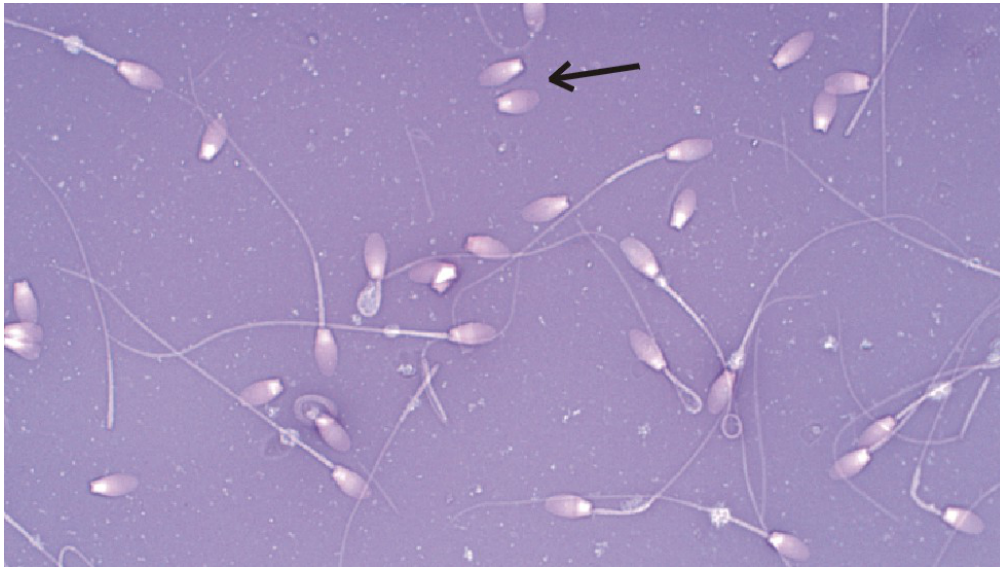

Figure 1. Photograph of spermatozoa in the first ejaculate from the clinical case. Note the abundance of detached heads (black arrow).

The stallion was collected multiple times over the subsequent three days. Semen parameters from those collections are presented in Table 2. Sperm concentration eventually stabilized at around 160 to 200 million sperm per ml and the total motility also stabilized at approximately 60 % by the 8th collection. The stabilization of the semen parameters indicate that most of the dead spermatozoa had been removed or 'cleaned out' by the 8th collection and we had reached 'daily sperm output'.

Table 2. Semen parameters for subsequent ejaculates from the clinical case.

Parameter	# 3	# 4	# 5	# 6	# 7	# 8	# 9	# 10	# 11
Volume (mls)	69	43	48	85	48	59	40	29	35
Concentration (millions/ml)	308	527	316	162	223	158	205	52	193
Motility (%)	4/2	25/21	27/17	23/17	32/26	62/57	61/50	49/39	62/55
Morphology (%)	29.5	32	29.5	37.5	30.1	36.5	38	28.5	34
Total # Sperm (billions)	21.25	22.66	15.17	13.77	10.7	9.32	8.20	1.51	6.76

The relationship between the increase in sperm motility and the decrease in the total number of sperm in the ejaculates is shown in the two graphs below (Figure 2). Sperm

numbers were very high in the first collections, but declined to more normal levels by the 8th to 11th collection. No motile sperm were noted in the first two ejaculates and sperm motility eventually plateaued by the 8th collection as the accumulated dead sperm were removed from the epididymides.

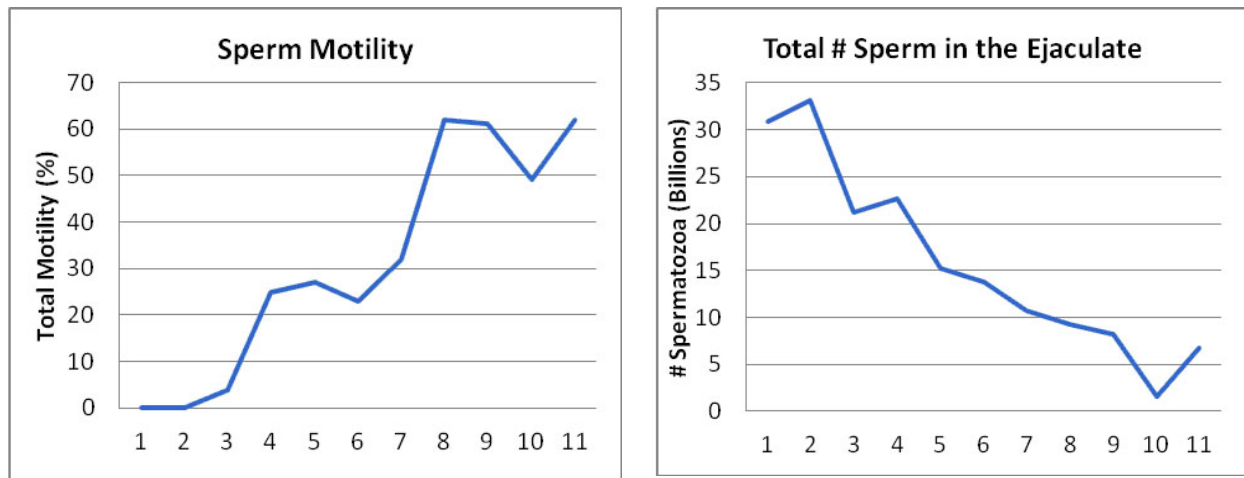


Figure 2. Total sperm motility (%) and the total number of sperm in the ejaculates during sequential semen collections on the clinical case.

Videos of Sperm Motility

Videos depicting the first, third, fourth and last semen collections from the stallion in this clinical case may be viewed at the following web addresses.

- 1st Collection - <http://www.youtube.com/v/COY/qilvAywc>
- 3rd Collection - <http://www.youtube.com/v/COY/IsSf3szckv8>
- 4th Collection - http://www.youtube.com/v/COY/oif_QExGdek
- Final Collection - <http://www.youtube.com/v/COY/jrCrC5mzxt8>

Take home message(s):

1. This stallion was determined to be a 'sperm accumulator stallion'. Affected stallions accumulate large numbers of spermatozoa in their epididymides, which are the highly coiled tubular sperm storage structures located just caudal to the testes.
2. In the normal series of events, spermatozoa are made in the testes, a process which takes approximately 57 days. Spermatozoa leave the testes and travel through the head and body of the epididymis and finally enter the tail of the epididymis where they are stored. The process of epididymal transport takes approximately 7 to 10 days. In the normal male, a combination of fluid flow and smooth muscle contractions of the epididymis/vas deferens slowly and constantly move sperm along the tubular tract out of the epididymis and they are eventually passed into the urethra and voided during urination.
3. However, sperm from some stallions do not move out of the epididymal tail and

accumulate in that structure in very large numbers. The accumulated sperm eventually die and start to break down, leading to poor motility and high percentage of detached heads during initial semen collection and evaluation.

4. 'Sperm accumulation' would also account for the low percentage of mares that became pregnant early in the previous breeding season for this stallion. It is possible that his ejaculates contained primarily dead and morphologically abnormal sperm early in the year. Once he was naturally 'cleaned out' by way of multiple, albeit infertile, live cover ejaculations his subsequent fertility was good and eventually lead to an acceptable seasonal pregnancy rate.
5. This year, it is anticipated that the stallion should do well in the same pasture breeding program now that he is 'cleaned out' and ejaculating a population of normal motile spermatozoa.

The goal of this report is to provide veterinarians and horse owners with an educational opportunity based on an actual clinical case presented to the Equine Reproduction Laboratory at Colorado State University. Publication of the report is sponsored by Animal Reproduction Systems, Chino, CA.

For more information on equipment and supplies available at ARS, please visit our website at www.arssales.com or call us at (800) 300-5143

Equipment described in this case report available at Animal Reproduction Systems includes:

CSU Model AV and supplies P/N: EAVK-110
<http://www.arssales.com/epc-av.html>

E-Z Mixin® "BF" Semen Extender P/N: EZM-BF
http://www.arssales.com/epi-mix_std_bf.html

Densimeter (590B) and supplies P/N: DENK-1001
<http://www.arssales.com/epe-590b-semen.html>

Hancock Stain P/N: HCS-101
<http://www.arssales.com/epe-hancock.html>